

Introduction

DMEK represents pure anatomic replacement surgery, and should be more predictable than DSAEK in the hyperopic shifts and topographic shifts that occur with resolution of corneal edema. The topographic effects and complications of eliminating edema in eyes with prior refractive surgery have not been reported with DMEK surgery. We asked the questions: "How predictable is the refractive result and topographic shifts of patients that have had refractive surgery before they received their DMEK?" and "Should we be doing concurrent cataract surgery and considering premium IOLs in these cases?"

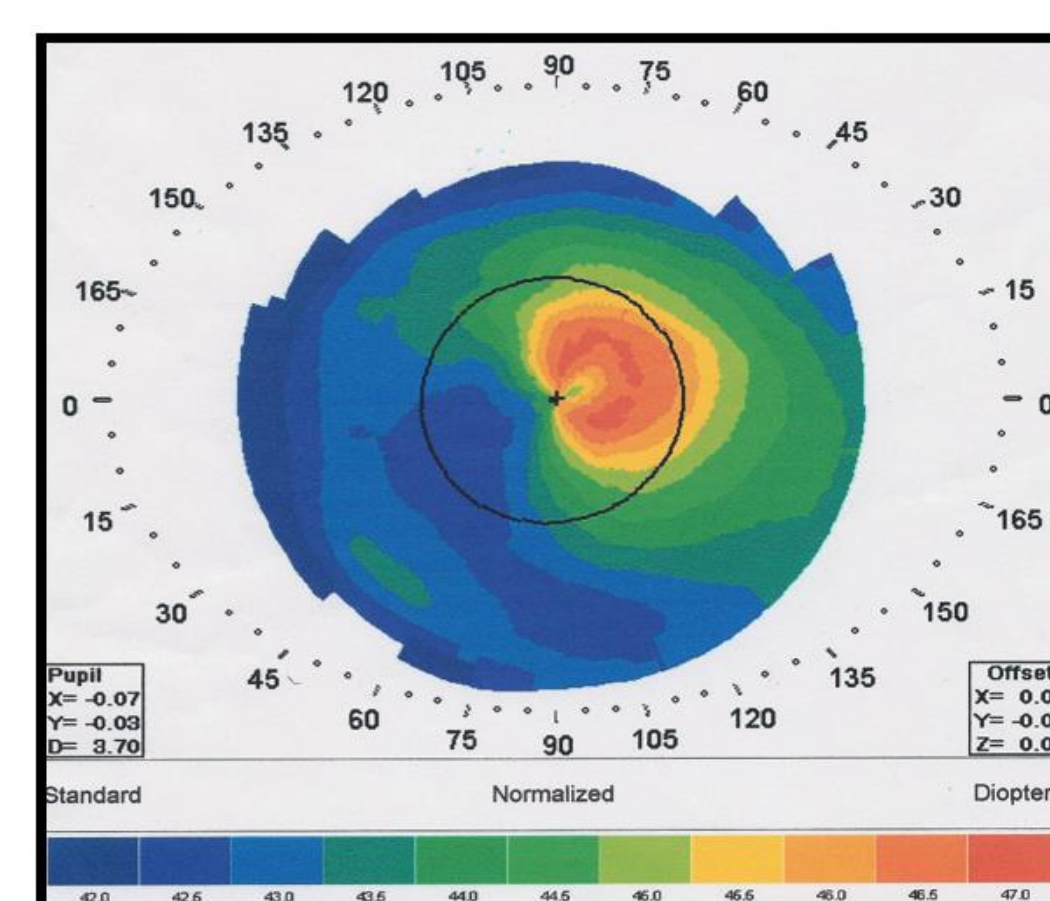
Methods

We did a retrospective analysis of all cases that had prior refractive surgery and then underwent DMEK surgery for corneal edema.

For our series, all eyes had Fuchs corneal dystrophy and underwent DMEK surgery at Devers Eye Institute between February 2012 and November 2014 using a Yoeuriek tap technique for unscrolling.

Best spectacle corrected vision (BSCVA) and Pentacam astigmatic and hyperopic changes were measured at 3 months or more postop. Re-bubble and graft failure events were recorded.

Patient with Fuchs and cataract- But also with a prior Lasik



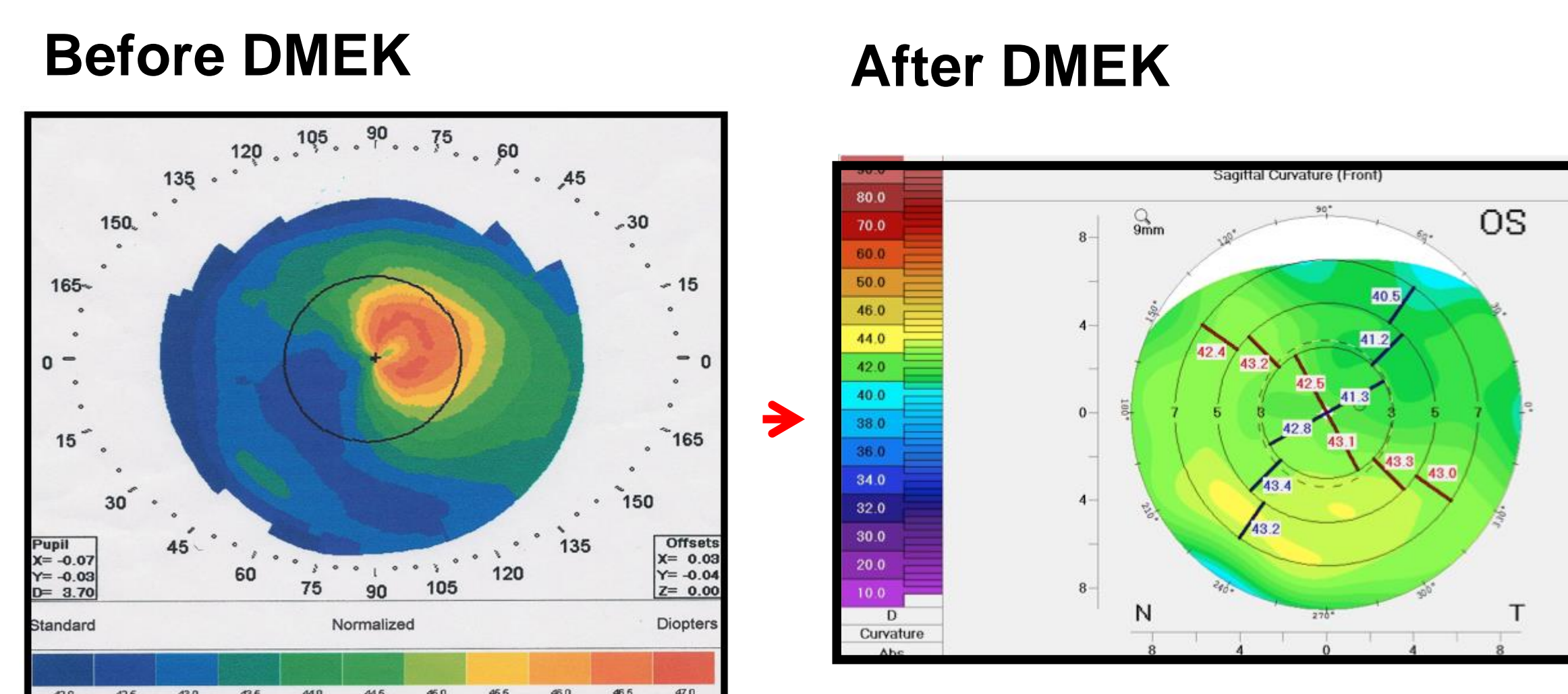
Initial Visit

MR OS: -1.00 + 0.75 X 20 = 20/60
 Topo Ks: OS: 45.0/44.56
 Astigmatism: (irregular) = 0.52 D
 Pachy OS: 620 um
 "Glare terrible" OS: 20/100

Phakic DMEK Left Eye

- Crystalline Lens left in place despite mild cataract because we have NO IDEA where the final K's will be after edema resolved after DMEK
- Cataract surgery to be done AFTER the DMEK clears the edema and K's stabilize

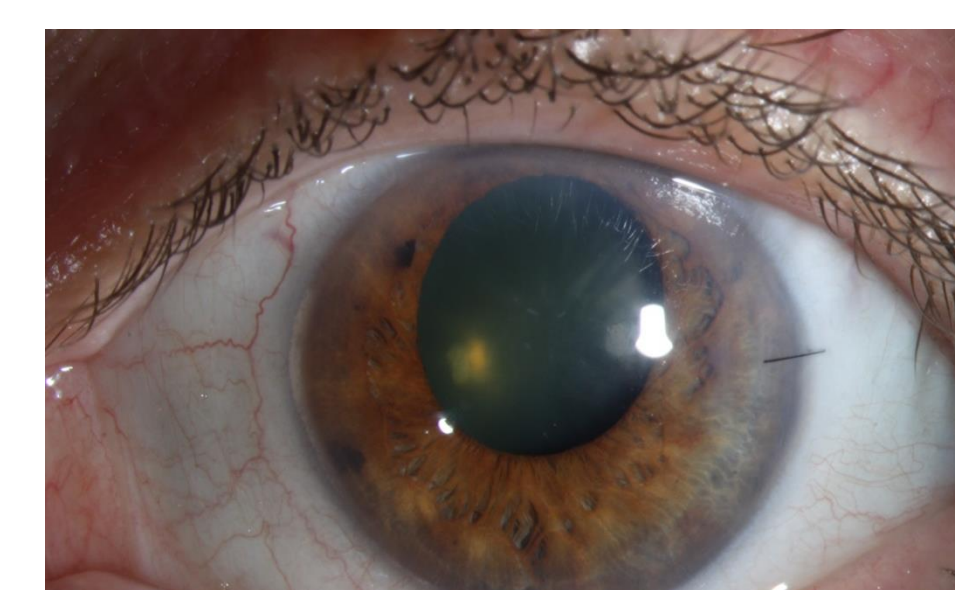Because this Fuchs Patient had LASIK surgery, she went from:



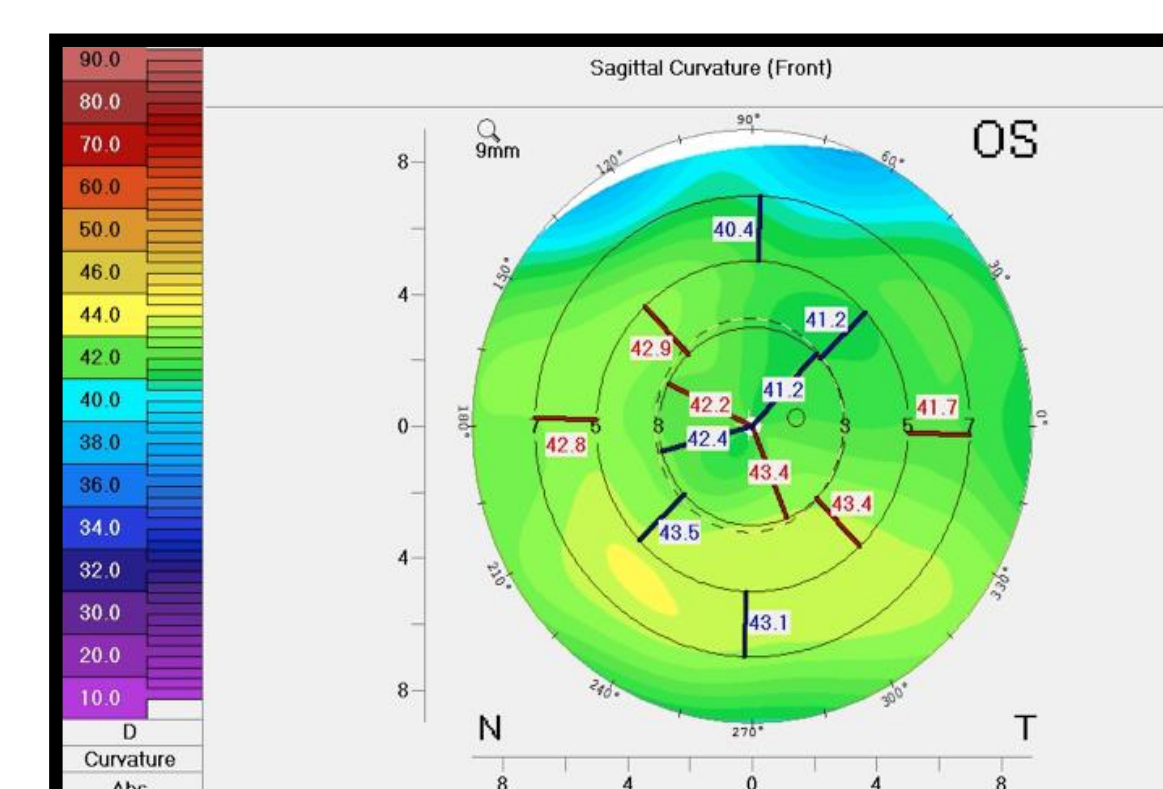
2.3 D of flattening from getting rid of the edema under the LASIK flap

Before DMEK	After DMEK
MR: -1.00 + 0.75 X 20 = 20/60	MR: +3.00 Sphere = 20/70
Mean K: 44.75	Mean K: 42.45
Astigmatism: (irregular) = 0.52 D	Astigmatism: (irregular) = 0.70 D

s/p Phakic DMEK with a clear cornea – Before Phaco of her cataract



Preop of Phaco
 MR: +3.00 sphere 20/70

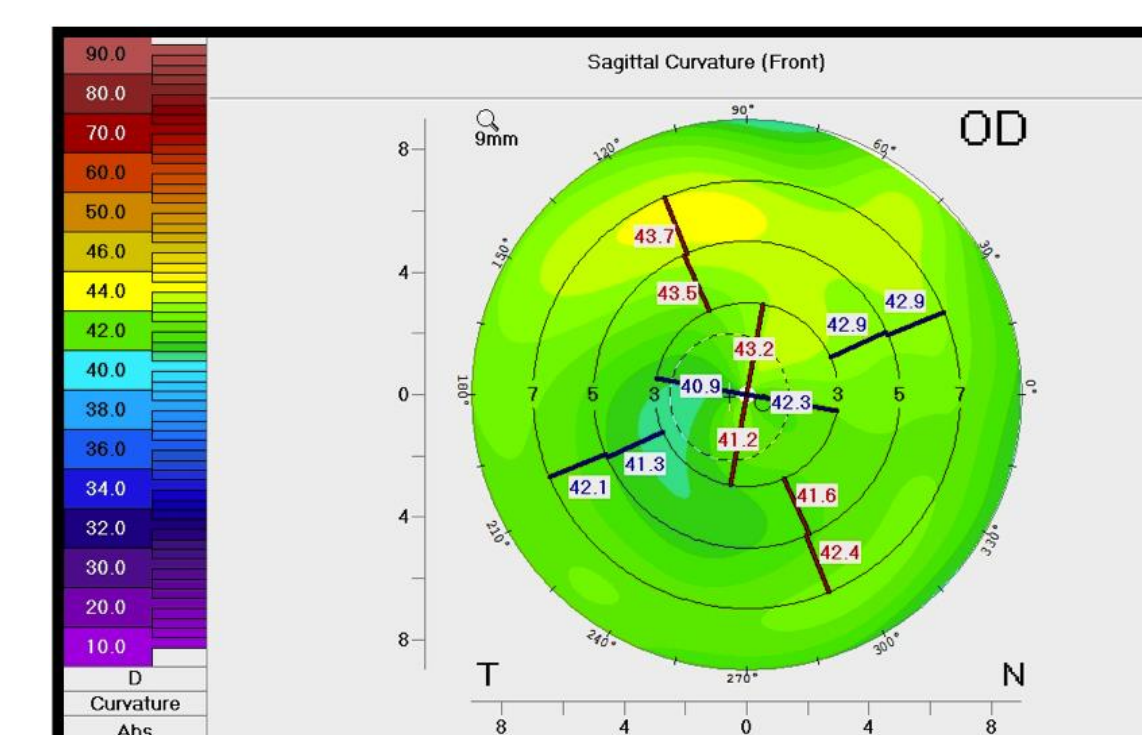


Phaco LE was done 3 months after DMEK— Using K's from AFTER the DMEK

After Phaco
 MR OS: -0.75 sphere = 20/25
 Vasc: 20/25-2
 Topo after phaco: Unchanged from After DMEK

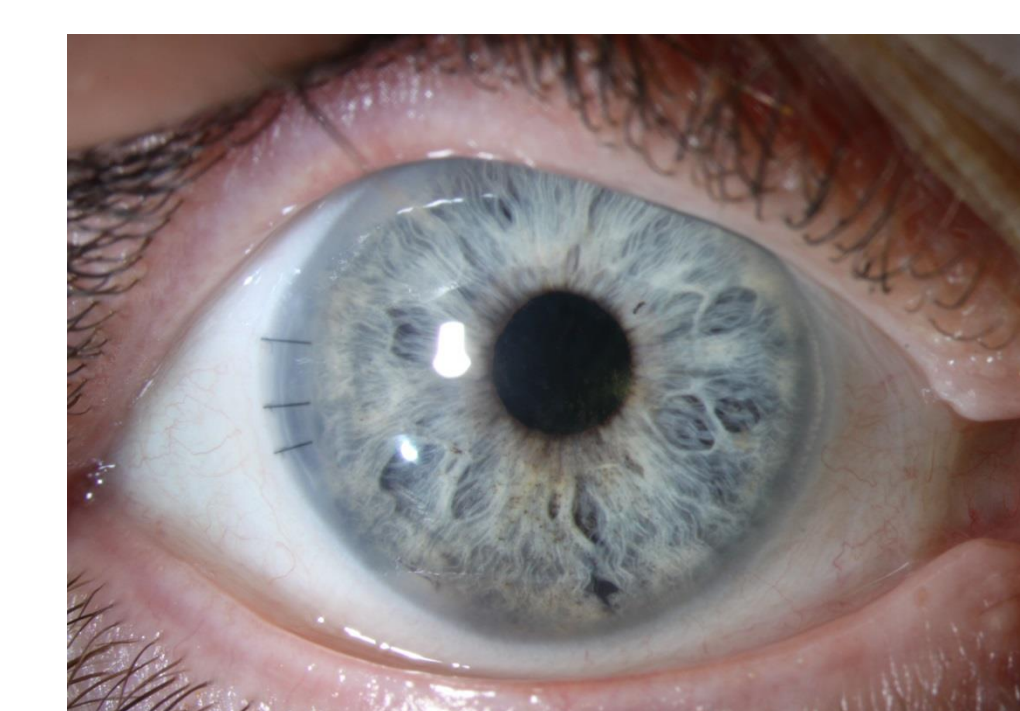
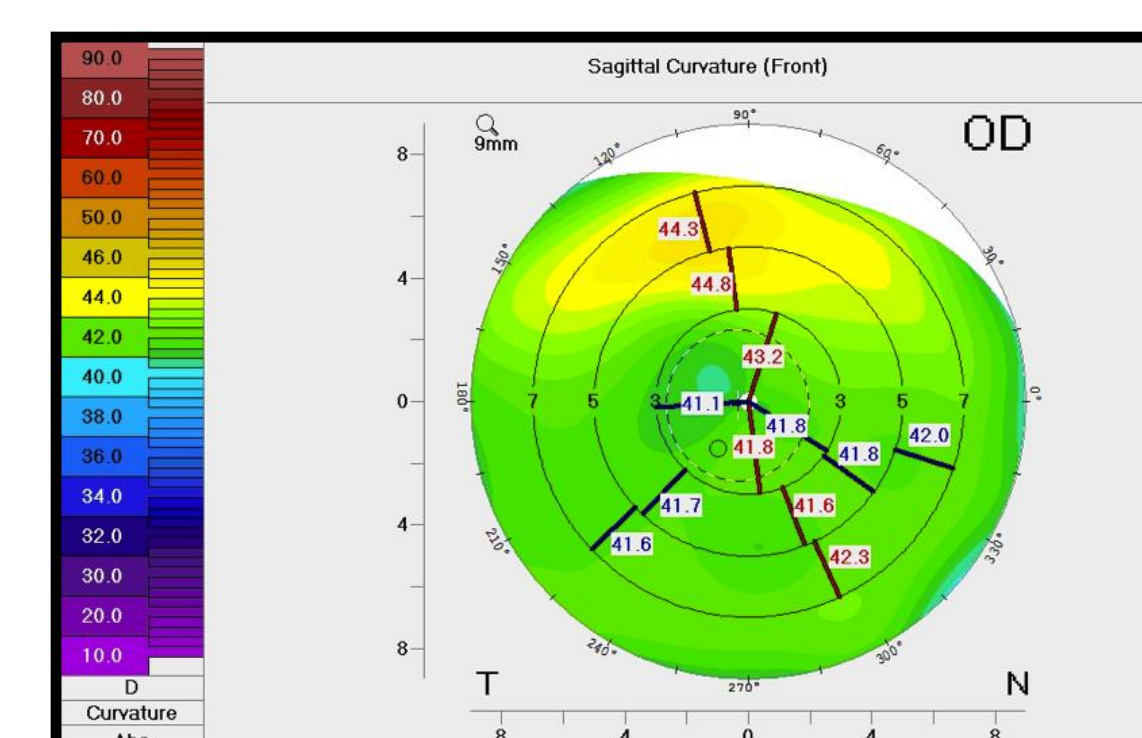
Patient happy with OS result – glad we did the phaco AFTER the DMEK!

DMEK in a Fuchs eye that had a prior PRK for Myopia, now with cataract and edema



MR OS: -0.75 sphere = 20/25
 BSCVA: 20/50
 .7 D of Astigmatism steep @ 99 degrees

- Patient underwent combined DMEK with Phaco of RE (IOL power chosen using LOWEST K from map to allow for hyperopic shifts)



Va without glasses = 20/20
 0.9 D of Astigmatism steep @ 74 degrees
 22 degree change in axis of astigmatism from preop

6 Weeks Post-Op DMEK with Phaco in eye with prior PRK over Fuchs

Results

There were 14 eyes evaluated. 10 eyes had prior Lasik surgery, 2 had photorefractive keratectomy (PRK), and 2 had prior radial keratotomies (RK) surgery. Mean BSCVA improved from preop 20/31 to 20/26 postop. (p=.026) Topographic astigmatism changed from preop levels by anywhere from 0.7 D of astigmatism increase to 3.1 D of astigmatism decrease. Steep axis changes from preop were unpredictable ranging from only 1 degree axis shift to 77 degrees axis shift of astigmatism. One eye was re-bubbled and there were no graft failures.

Conclusion

- 1) DMEK improves vision in eyes with edema and a history of prior refractive surgery.
- 2) Correction of corneal edema may unmask large shifts in corneal topography in the presence of a Lasik flap and significant changes in axis of astigmatism in eyes with prior PRK.
- 3) Triple procedures and especially toric lenses may be unpredictable in eyes with a history of prior Lasik surgery. A triple procedure in Fuchs eyes with prior PRK may be more predictable for spherical power, but large shifts in axis of astigmatism can occur making toric lenses less desirable.
- 4) In eyes with prior refractive surgery, edema, and cataract: consideration should be given to doing the DMEK surgery FIRST, waiting 6 weeks or more for the topography to stabilize, then doing the cataract surgery later when topography is stable and accurate.
- 5) Lasik should not be done in any patient with Fuchs's corneal dystrophy who may require endothelial replacement surgery even years later. PRK may be a viable option for Fuchs patients, but analysis of results in a larger series of DMEK in prior PRK eyes is desirable before making this determination.